

**Case Report:**

**A case of penetrating ocular injury by metallic foreign body and importance of multidisciplinary approach in its management**

**Dr Archisman Ponda, Dr Soumyo Swarup Chatterjee, Dr Anjalika Shekhar, Dr Anulekha Banerjee, Dr Deepak Agarwal**

Name of the Institute/college: Regional Institute of Ophthalmology, Medical College and Hospital, Kolkata

Corresponding author: Dr Archisman Ponda

---

**Abstract:**

Intraocular foreign objects can be seen in different forms such as: metallic, non-metallic and organic such as wood or vegetable matter. In general, visually innocuous inert and sterile bodies can be left in situ. But sometimes atypical penetrating injuries require prompt and adequate management for saving the patient's life, often necessitating sacrifice of the globe. This retrospective case report reviews the appearance and management of an uncommon metallic foreign body injury with retention of the foreign body in situ, which warranted a multidisciplinary approach in a prudent manner.

Key Words: Intraocular foreign body; metallic foreign body; Penetrating ocular injury

---

**Case history:**

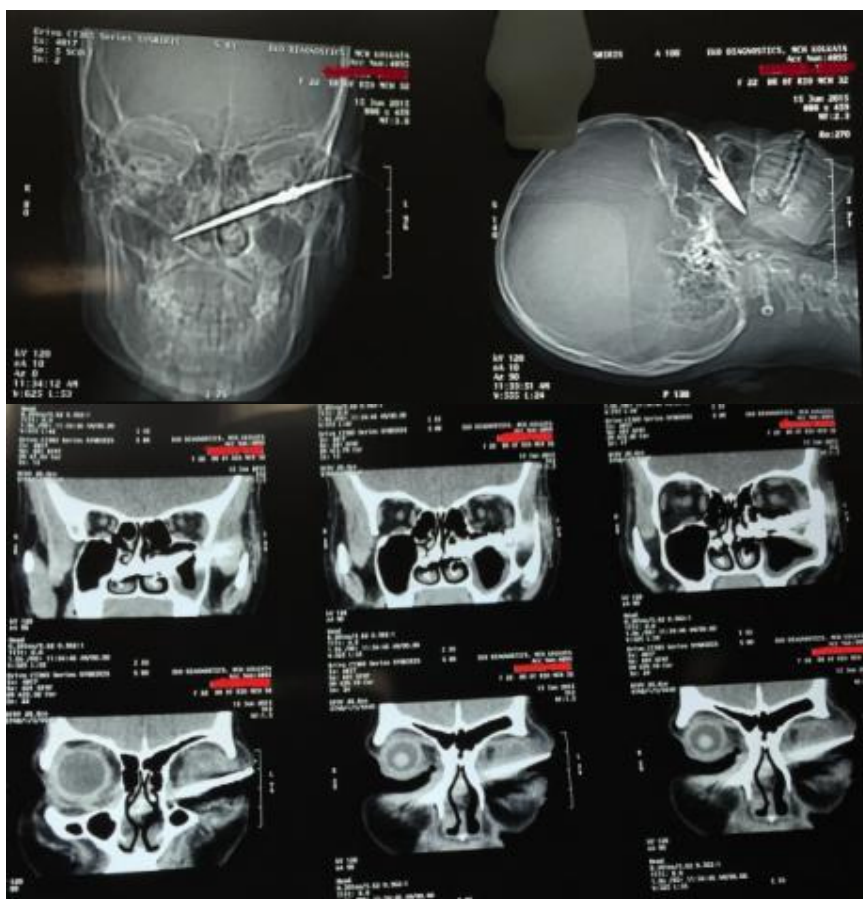
A 22 year old female patient came to the Ophthalmology ER in an acute state of severe pain over left eye and bleeding from nostrils. She gave a history of injury by some sort of a metallic arrowhead 12 hours prior. On examination at the ER, the rear end of a thin metallic rod was seen to be protruding out of infero-temporal aspect of the sclera of left eye. The patient resisted any degree of passive opening of the palpebral aperture. Fortunately the epistaxis was controlled by local

application of pressure. No further immediate manipulation was done for fear of a rebleed. CT scan of the orbit showed a fairly long metallic arrow with broad flanges that entered left orbit, punctured the globe and the inferomedial orbital wall, then after proceeding in a slightly postero-inferior course, fractured the posterior part of nasal septum and finally went through the ethmoidal sinuses lodging on the wall of the maxillary antrum of the right side.

**Indian Journal of Basic and Applied Medical Research**

Is now with

**IC Value 5.09**



An urgent Otorhinolaryngological consult was sought for. Upon consensus by both teams of surgeons, the patient was rushed to surgery. Unfortunately it was evident that the eye could not be saved. Initially a partial evisceration was done, removing as much globe contents as possible without disturbing the foreign body. The stem of the arrow was then released by a small incision over the upper eyelid near the left canthus. The widest part of the flange was inside the orbit and was released by an incision over the sclera. After disimpaction the arrowhead could be pulled out with gentle manipulation without any further bleeding episode. A nasal endoscope was introduced. Nasal mucosa barring the injury site was edematous but otherwise normal. No post nasal bleed was evident. Nasal pack was placed in both nostrils to prevent mucosal synechiae. Evisceration

was completed and remaining uveal tissue was carefully removed. Finally the sclera and conjunctiva was sutured with 4-0 vicryl. Post operatively she was put on extensive parenteral antibiotic coverage, systemic steroids and analgesics. Tetanus toxoid injection was given. Nasal packs were removed on 4<sup>th</sup> post-operative day. No further complications were seen.

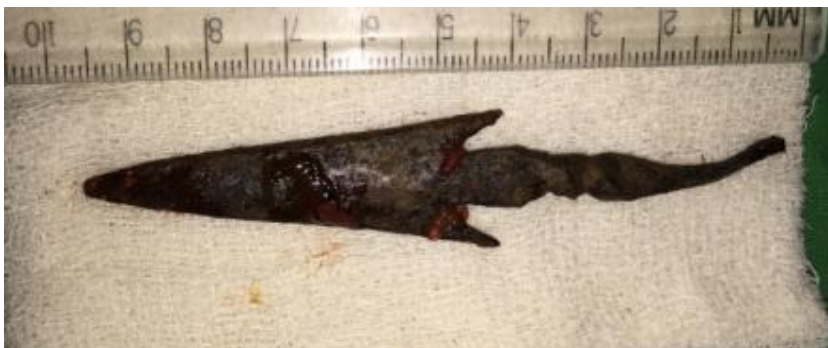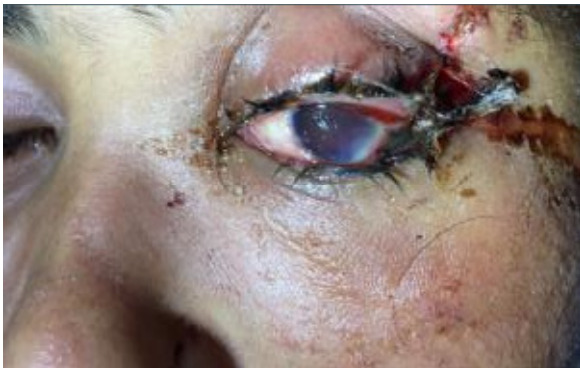**Discussion:**

Under normal circumstances, an intraocular foreign body should be removed unless: 1) It is inert and/or sterile, 2) Little damage has been done to vision; and 3) The process of removal will almost inevitably destroy sight.[1] Ancillary aids are often proved vital in assessing penetrating and retained foreign body injuries to the globe.[2] Especially the role of orbital CT scans cannot be overemphasised in ascertaining the depth, nature and extent of the

injury and also the particular shape and size of the foreign body in question.[3] The pertinence of this case report lies in the fact that the severity of penetrating and retained metallic foreign body injuries are often underestimated by the ophthalmic surgeon in the ER because of the vast number of 'typical' penetrating injuries that are successfully managed in the emergency OT without any significant cross-discipline comorbidities.

In this particular case, the peculiar nature of the offending foreign body presented a unique challenge to the attending ophthalmologists. The patient could not provide any clear detail about the iron object that injured her left eye and the small protruding rear end of the object was lying just a few millimetres outside the palpebral aperture. Crucially, no attempt was made to manoeuvre and pull out the object in the ER. In retrospect this

could have further injured the fine ethmoid and maxillary bone structure with potentially disastrous haemorrhage. Additionally, the proximity of the arrow's metallic flange to the Ethmoidal roof retrospectively indicates that undue manipulation of the arrow could have injured the cribriform plate with devastating CSF leakage. Unfortunately in this case, it was evident that that broad flange of the arrow could not be removed without sacrificing the globe contents and thereby possibility of retaining any vision for the patient. However, from the ENT perspective, lateral rhinotomy by an external approach which would have further aggravated the morbidity of the surgery and cosmetic prognosis, was not necessary. The fellow right eye was normal and having 6/6 visual acuity on discharge of the patient.



**Conclusion:**

Intraocular foreign bodies may present in multiple ways, sometimes atypically and with peculiarly shaped objects, complicating the management protocol. CT scan is the primary diagnostic

modality in case of metallic foreign bodies. Prompt presentation to the ophthalmologist combined with early surgical intervention with a foresight of multidisciplinary approach form the cornerstone of management.

**References**

- [1] R. Shihota and R. Tandon, Eds., Parsons' Diseases of the Eye, 20th ed., ELSEVIER, 2007, p. 374.
- [2] R Lagalla, L Manfrè, A Caronia, F Bencivinni, C Duranti, F Ponte, "Plain film, CT and MRI sensibility in the evaluation of intraorbital foreign bodies in an in vitro model of the orbit and pig eyes," European Radiology, vol. 10(8), pp. 1338-1341, 2000.
- [3] Hamilton A, Meena M, Lawlor M, "An unusual case of intraorbital foreign body and its management," Int Ophthalmol, pp. 65-71, 2013.